Lightning Learning: Trifascicular Block

http://em3.org.uk @EM3FOAMed youtube.com/em3orguk

#EM3
East Midlands Emergency Medicine Educational Media

WHAT?

Trifascicular block is a combination of heart block *with* a bifascicular block and can be complete or incomplete.

Bifascicular block is diagnosed by the presence of right bundle branch block with *either* left anterior fascicular block (common) *or* left posterior fascicular block (rare).

LAFB results in left axis deviation and **LPFB** in right axis deviation.

Complete trifascicular block:
3rd degree heart block in the presence of bifascicular block.

Incomplete trifascicular block:
1st or **2nd** degree heart block with bifascicular block.

It can also be **RBBB** with alternating **LAFB** and **LPFB.**

WHY?

Incomplete trifascicular blocks can convert into complete heart block.

Any patient who presents with a trifascicular block on their ECG will need a medical or cardiology review.

Many of these patients will require pacing, but be sure to review all medications.

Trifascicular block can result from:

- Ischaemic heart disease
- Congenital heart disease
- Hyperkalaemia
- Digoxin toxicity

HOW?

FOAMed on fascicular blocks:
http://bit.ly/2nsPK8i

Life in the Fastlane: ECG library (trifascicular block)
http://bit.ly/2AoXFsf

Right bundle branch block characteristics

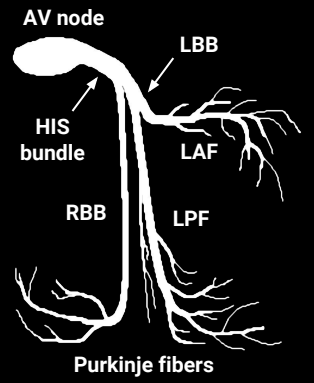

	Normal Axis 0 to 90	Left Axis Physiological 0 to -30	Left Axis Pathological -30 to -90	Right Axis 90 to 180	Extreme Axis -90 to -180	Indeterminate Axis ?
Lead I						
Lead II						
Lead III						

Author: Darren Whitelaw **Date:** 04.12.2017 **Version:** 1.0