



WHAT?

Intussusception is the most common cause of *intestinal obstruction* in children aged from **5 months to 3 years**.

Intussusception accounts for **up to 25%** of *all abdominal emergencies* in children up to the age of 5.

- Acute presentation to the Emergency Department
- Most common in boys
- Bowel “**telescopes**” in on itself (see diagram)
- No known cause identified, but may be linked to infection

WHY?

Spasms of **acute colicky pain** followed by lethargy/paleness.

?palpable “**sausage shaped**” mass, right upper quadrant and ‘red currant’ stools.

Reduced:

- bowel sounds.
- *blood flow* to the affected part of the bowel.
- *function* and bruising damage to the bowel tissue.

Causing:

- *dehydration* due to vomiting.
- *ischaemia* from lymphatic and venous obstruction.

HOW?

Management:

NGT insertion

IV fluids/correct dehydration

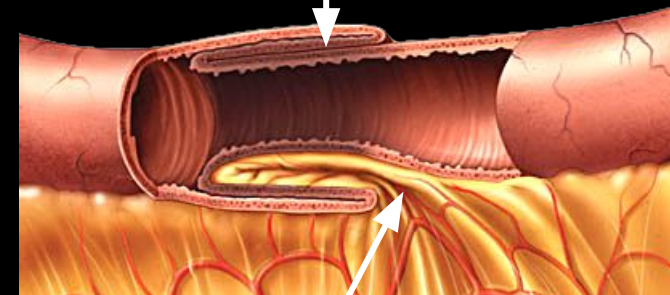
Abdo x-ray

Repair:

Air enema with analgesia

Surgical intervention

Intussuscepted section of small intestine



Constricted blood supply