

Lightning Learning: Basic Chest X-rays in Adults

em3.org.uk

     @EM3FOAMed

University Hospitals of Leicester  #EM3
East Midlands Emergency Medicine Educational Media

DETAIL Name Type of film
 DOB Study date/time

RIPE Rotation Inspiration
 Picture Exposure

SOFT TISSUES Ribs, sternum, spine, clavicles Breast shadows
 Calcification

AIRWAY

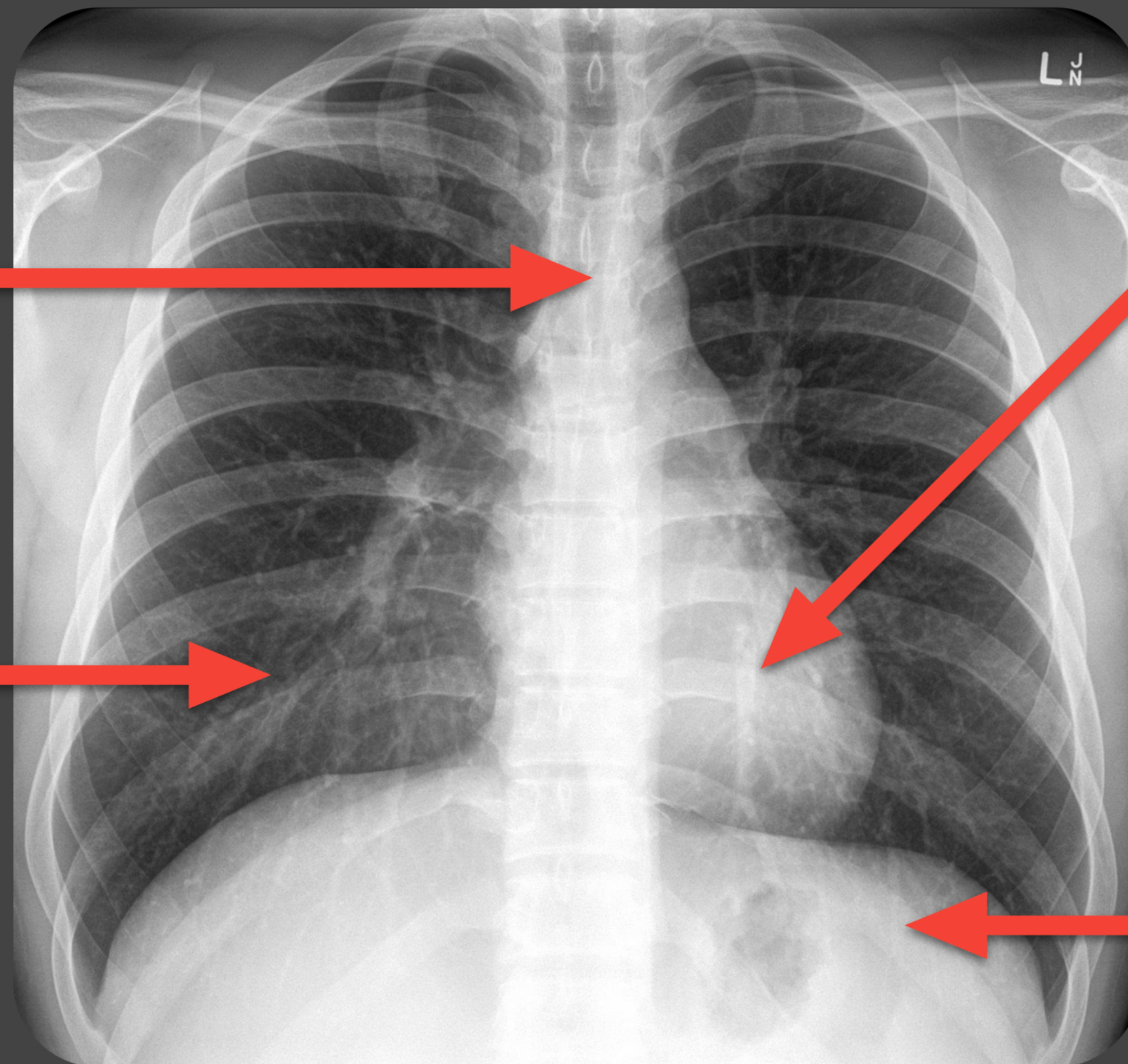
- Trachea
- Mediastinal width
- Aortic knob

DO NOT MISS:
DEVIATED TRACHEA

BREATHING

- Lung field outlines
- Symmetry
- Pleural

DO NOT MISS:
PNEUMOTHORAX



CIRCULATION

- Heart size on PA film
- Heart borders
- Heart shape

DIAPHRAGM

- Hemidiaphragm levels
- Diaphragm shape or contour
- Costophrenic angles

DO NOT MISS:
SUBDIAPHRAGMATIC
FREE AIR (PNEUMO-
PERITONEUM)

EXTRAS Nasogastric tube ECG electrodes Foreign body
 Pacemaker PICC line ET tube

Source: litfl.com/drsabcde-of-cxr-interpretation

Image courtesy of Assoc Prof Frank Gaillard, [Radiopaedia.org](https://radiopaedia.org), rID: 8090