



LE FORT FRACTURES

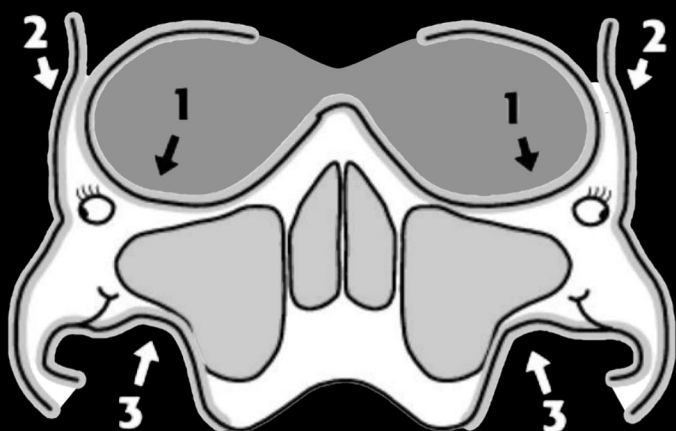
By Dr. Sarah Edwards
@drsarahedwards

#EM3
East Midlands Emergency Medicine Educational Media

Le Fort Fractures (LFF) are fractures of the mid face.

They collectively involve separation of all or a portion of the mid face from the skull base. The pterygoid plate of the sphenoid bone needs to be involved as they connect to the mid face to the sphenoid bone dorsally.

RADIOGRAPHIC FEATURES



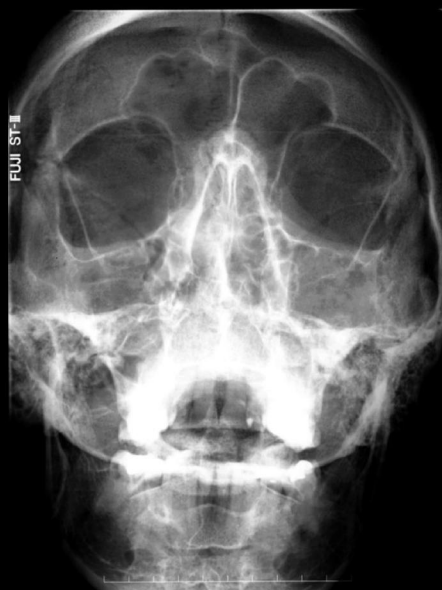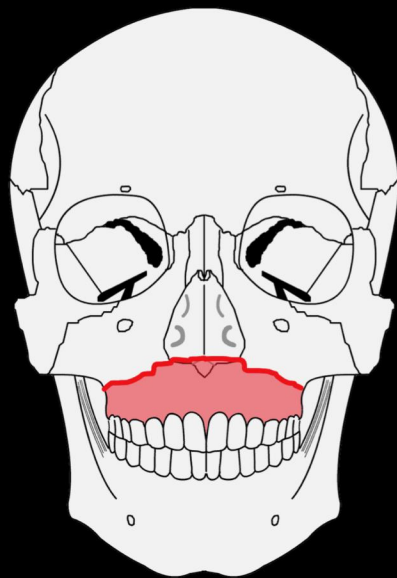
3 lines to aid evaluation in maxillofacial fractures on an occipitomental(OM) skull x-ray

1. Orbital line traces the inner margins of the lateral, inferior, and medial orbital walls, and the nasal arch

2. Zygomatic line traces the superior margin of the zygomatic arch and body, extending along the frontal process of the zygoma to the zygomaticofrontal suture

3. Maxillary line traces the inferior margin of the zygomatic arch, body, and buttress, and the lateral wall of the maxillary sinus. Lines 2 + 3 form "Dolan's elephant"

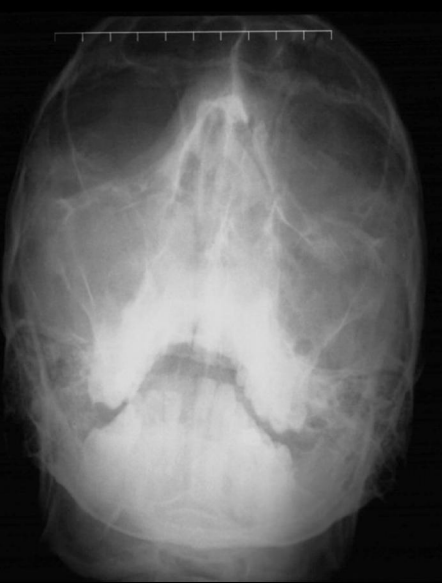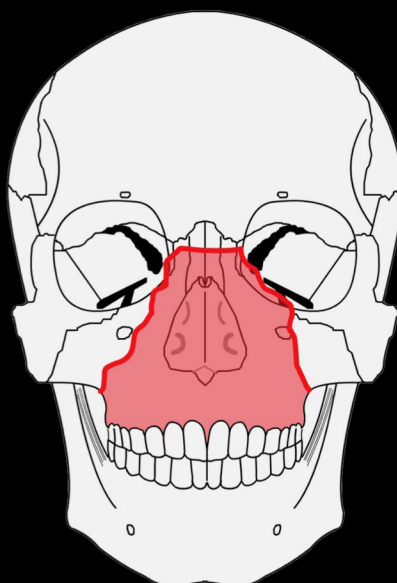
DOLAN'S LINES



LE FORT TYPE I Floating Palate

Horizontal maxillary fracture, separating the teeth from the upper face

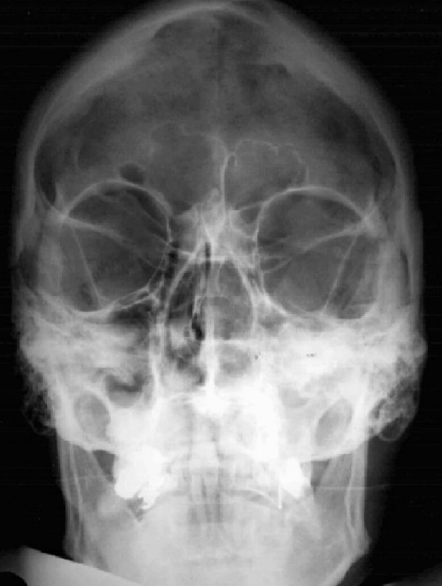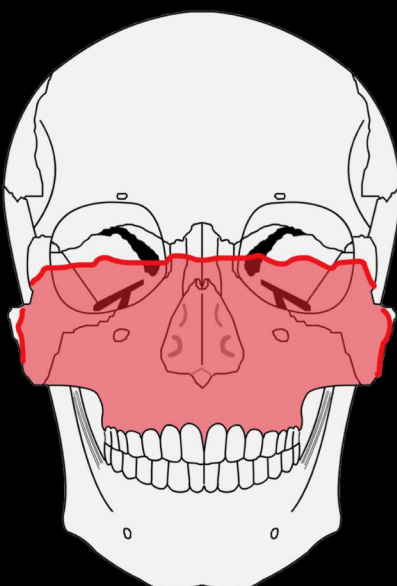
Fracture line passes through the alveolar ridge, lateral nose and inferior wall of the maxillary sinus



LE FORT TYPE II Floating Maxilla

Pyramidal fracture, with the teeth at the pyramid base, and nasofrontal suture at its apex

Fracture arch passes through the posterior alveolar ridge, lateral walls of maxillary sinuses, inferior orbital rim and nasal bones



LE FORT TYPE III Floating Face

Craniofacial disjunction

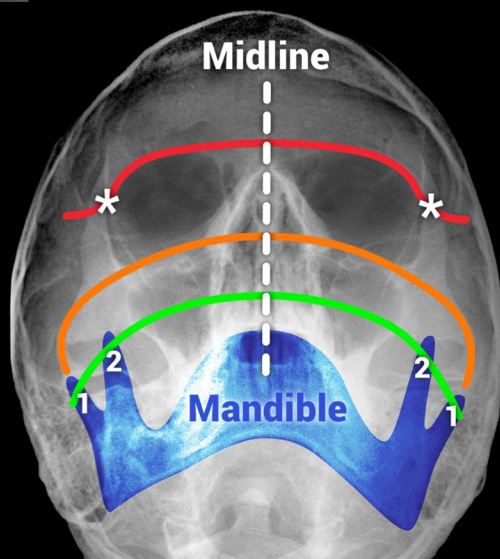
Transverse fracture line passes through nasofrontal suture, maxillo-frontal suture, orbital wall, and zygomatic arch / zygomaticofrontal suture

Upper RED line: passes through the zygomatic-frontal sutures (asterisks) and across the upper edge of the orbits.

Middle ORANGE line: follows the zygomatic arch (elephant's trunk), crosses the zygomatic bone and follows in inferior orbital margins to the opposite side.

Lower GREEN line: passes through condyle (1) and coronoid process (2) of the mandible and through the lateral and medial walls of the maxillary antra.

Mid line - used to assess symmetry



MCGRIGOR-CAMPBELL LINES

References
1. Radiopaedia: <https://radiopaedia.org/articles/le-fort-fracture-classification>
2. Accident and Emergency Radiology: A survival guide. 3e. by Nigel Raby.